

Management of an Infected Neuropathic Ulceration

CASE

On September 13, 2023, a 66-year-old Caucasian female presented with an infected neuropathic ulceration on her right great toe. She has a past medical history of acid reflux and neuropathy, and reports no recreational drug use, smoking, and occasional alcohol use. The patient reported a possible injury in July 2023, and has been self-treating with triple antibiotic ointment. Increased redness, warmth, swelling, drainage, and odor prompted her visit. This case highlights the comprehensive management and positive outcomes achieved over four weeks.

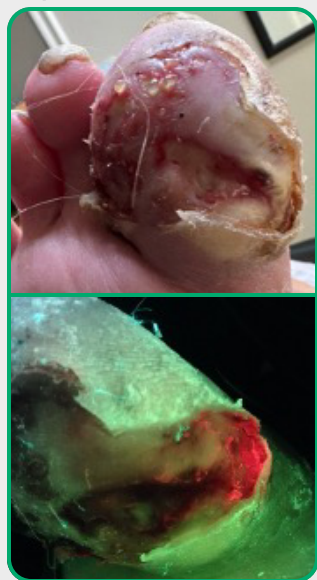
Physical examination revealed palpable pulses on the right, no hair growth, mild edema, and limited neurological protective threshold. The malodorous ulcer exhibited a hyperkeratotic rim with undermining but no bone or tendon probe, moderate serosanguinous drainage, and cellulitis on periwound skin. On presentation, the wound measured 5cm x 3cm x 0.2cm. The x-ray showed no abnormalities. Due to the chronic nature of the wound, the decision was made to assess the wound utilizing the MolecuLight bacterial fluorescence imaging device which revealed a red hue along the ulceration site. This is indicative of moderate to heavy bacterial presence.

TREATMENT

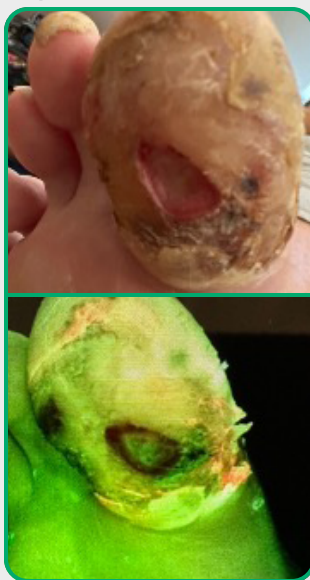
An excisional debridement and biopsy was performed. Biopsy results were positive for *Corynebacterium*, *Streptococcus*, and *Enterobacter*. revvyve™ antimicrobial gel was prescribed for daily application with dry dressings, along with a postoperative shoe and oral antibiotics. At subsequent visits debridement was repeated, and on the second follow-up visit a CAM walker was prescribed.

RESULTS

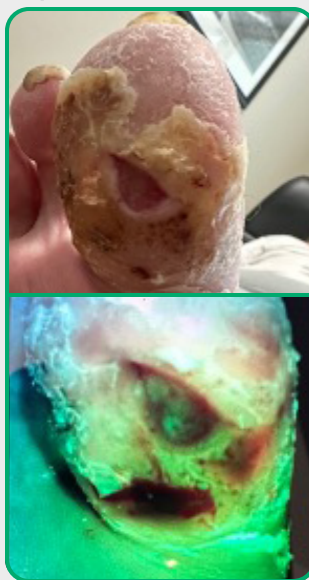
Sept. 13, 2023



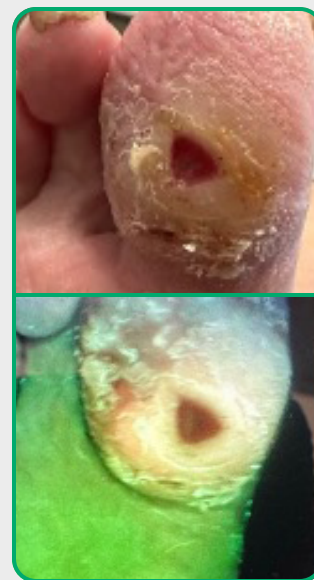
Sept. 21, 2023



Sept. 28, 2023



Oct. 11, 2023



This case demonstrates the successful management of an infected neuropathic ulceration. Thanks to MolecuLight, the effectiveness of the revvyve antimicrobial gel and the overall treatment plan could be visualized. There was a large decrease in bacterial presence after just one week of application. No red hue was visible by the second follow-up visit. The wound size reduced to 0.8 cm X 0.7 cm X 0.2 cm by the third follow-up visit, a 96% reduction in wound area in the four weeks of treatment. The patient stated that the gel was easy to apply and clean off with dressing changes. The reduction in wound size and absence of complications underscore the effectiveness of the treatment plan.