Current Work

Poster Number:

15266

Abstract Title:

A MODIFIED COLLAGEN GEL DRESSING RESOLVES WOUND INFLAMMATION THROUGH MICRORNA-21 DEPENDENT M2 MACROPHAGE POLARIZATION

Presented at: SAWC/WHS Spring 2016 Conference in Atlanta, GA

The works were partly supported by Southwest Technologies Inc. by means of an unrestricted gift where the donor had no control over scientific experiments or reporting.

Rev. C 3-16

OP-106B

Featured on the Cover

Wound Repair And Regeneration

Volume 22, Issue 6, pages 720–729, November-December 2014

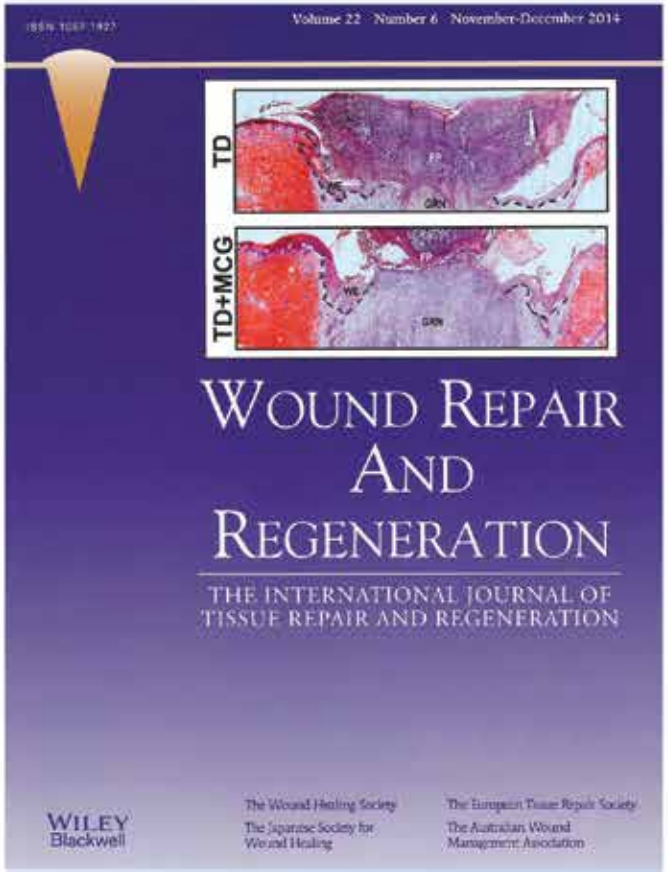

"A modified collagen gel dressing promotes angiogenesis in a preclinical swine model of chronic ischemic wounds"

southwest technologies inc.
1746 Levee Road, North Kansas City, MO 64116
phone: (800) 247-9951 phone: (816) 221-2442 fax: (816) 221-3995
email: info@elastogel.com • website: www.elastogel.com

Findings of the application of Stimulen® Gel (Modified Collagen Gel or MCG) on the wound healing process in three different animal wound models.

Increased recruitment of inflammatory cells to the wound-site, an important step in preventing infection and promoting healing of the wound.

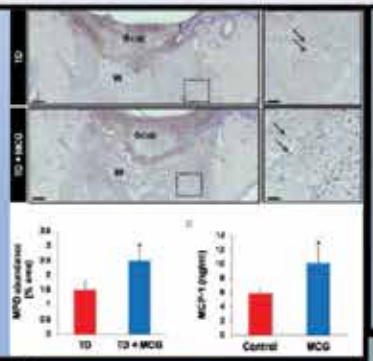

Increased recruitment of endothelial cells that form new blood vessels

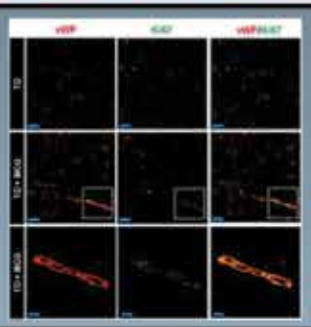

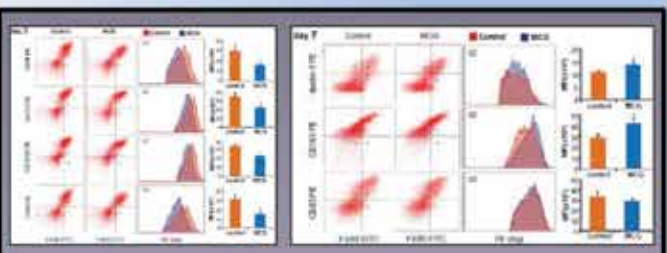

Enhanced transition of inflammatory cells from a pro-inflammatory to a reparative state, allowing for a timely healing response.

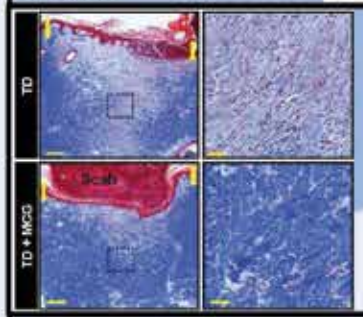

Higher abundance of mature collagen fibers, associated with improved biomechanical properties

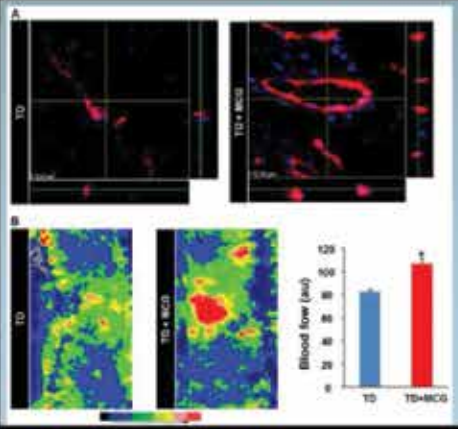

Formation of new blood vessels and increased blood flow to the wound

Improved engulfment by inflammatory cells, a process that is essential for the clearing of harmful entities and advancement of the wound healing process.

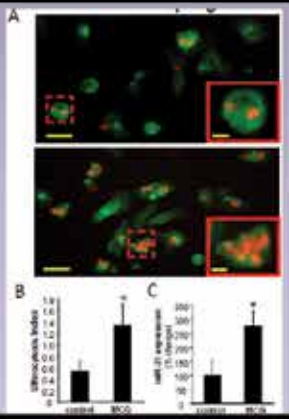

Greater collagen I:III ratio in the wound, indicative of greater tensile strength and resistance to reopening caused by shear stress.



Increase in the length of rete ridges reestablishes more healthy skin that is well nourished and more resistant to reopening

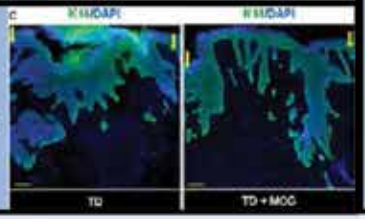

Recruitment of the reparative type of immune cells that are responsible for preventing excessive inflammation and further damage

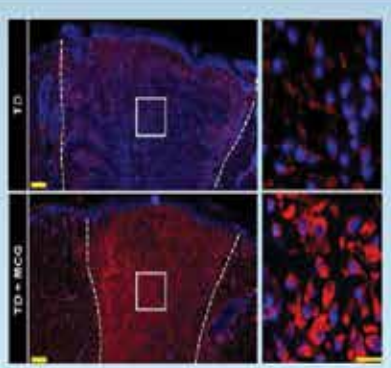

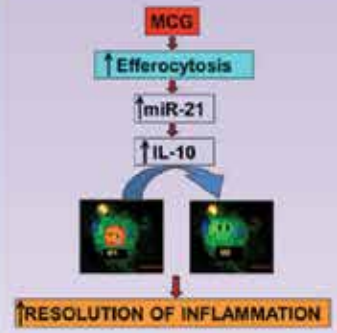

Resolution of wound inflammation through microRNA-21 dependent M2 macrophage polarization

Elgharably H, Roy S, Khanna S, Abas M, Ghatak PD, Das A, et al. A modified collagen gel enhances healing outcome in a pre-clinical swine model of excisional wounds. Wound Repair Regen 2013; 21: 473–81.

Elgharably, H., Ganesh, K., Dickerson, J., Khanna, S., Abas, M., Ghatak, P. D., Dixit, S., Bergdall, V., Roy, S. and Sen, C. K. A modified collagen gel dressing promotes angiogenesis in a preclinical swine model of chronic ischemic wounds. Wound Repair and Regeneration 2014; 22: 720–729.

Abstract Title: A MODIFIED COLLAGEN GEL DRESSING RESOLVES WOUND INFLAMMATION THROUGH MICRORNA-21 DEPENDENT M2 MACROPHAGE POLARIZATION (SAWC/WHS Spring 2016) Poster# - 15266; **Selected for Research Poster Critique for AAWC walking research poster grand rounds**

Wound Healing Society

Improving wound healing outcomes through science, education, and communication

Abstract ID: WHS20140226
Session Name: P2.05 - Emerging Technologies - II
Session Date and Time: Saturday, April 26, 2014; 10:30 a.m. - 11:30 a.m.

A MODIFIED COLLAGEN GEL DRESSING PROMOTES ANGIOGENESIS IN A PRE-CLINICAL SWINE MODEL OF CHRONIC ISCHEMIC WOUNDS

P. D. Ghatak[1], H. Elgharably[1], J. Dickerson[1], S. Khanna[1], M. Abas[1], S. Roy[1], V. Bergdall[2], C. K. Sen[1]; [1]The Ohio State University Medical Center, Comprehensive Wound Center, Davis Heart & Lung Research Institute, Centers For Regenerative Medicine And Cell Based Therapies, Columbus, OHIO, USA; [2]The Ohio State University, University Laboratory Animal Resources, Columbus, OHIO, USA

Introduction: We recently performed proteomic characterization of a modified collagen gel (MCG) dressing and reported promising effects of the gel in healing full-thickness excisional wounds. In this work, we test the translational relevance of our aforesaid findings by testing the dressing in a swine model of chronic ischemic wounds recently reported by our laboratory. Full thickness excisional wounds were established in the center of bi-pedicle ischemic skin flaps on the backs of animals. Ischemia was verified by Laser Doppler imaging and MCG was applied to the test group of wounds. Seven days post-wounding, macrophage recruitment to the wound was significantly higher in MCG-treated ischemic wounds. In vitro, MCG up-regulated expression of Mrc-1 (a reparative M2 macrophage marker) and induced the expression of anti-inflammatory cytokine IL-10 and of β-FGF. Furthermore, analyses of wound tissues 7 days post wounding showed up-regulation of TGF-β, VEGF, vWF, and collagen type I expression in MCG-treated ischemic wounds. At 21 days post-wounding, MCG-treated ischemic wounds displayed higher abundance of proliferating endothelial cells that formed mature vascular structures and increased blood flow to the wound. Fibroblast count was markedly higher in MCG-treated ischemic wound-edge tissue. In addition, MCG-treated wound-edge tissues displayed higher abundance of mature collagen with increased collagen type I:III deposition. Taken together, MCG helped mount a more robust inflammatory response which resolved in a timely manner, followed by an enhanced proliferative phase, angiogenic outcome and post-wound tissue remodeling. Findings of the current study warrant clinical testing of MCG in a setting of ischemic chronic wounds.

Wound Healing Society

Improving wound healing outcomes through science, education, and communication

Abstract ID: WHS20140165
Session Name: H2.06 - Biomaterials
Session Date and Time: Thursday, April 24, 2014; 9:00 a.m. - 10:30 a.m.

A MODIFIED COLLAGEN GEL IMPROVES ACUTE PHASE INFLAMMATION AND RESOLUTION RESPONSE IN WOUND HEALING

A. Das[1], M. Abas[1], S. Roy[1], C. K. Sen[1]; [1]The Ohio State University Medical Center, Comprehensive Wound Center, Davis Heart & Lung Research Institute, Centers For Regenerative Medicine And Cell Based Therapies, Columbus, OHIO, USA

Introduction: Our previous work has demonstrated improved wound healing outcomes in excisional and ischemic porcine wounds following the use of modified collagen gel (MCG) dressing. These studies demonstrated that MCG dressed wounds had greater infiltration of inflammatory cells in the early inflammatory phase followed by timely and efficient resolution. The objective of the current work was to understand the mechanism of action of MCG on the host wound inflammatory cells in early and late inflammatory phase. Polyvinyl alcohol (PVA) sponges containing either MCG or saline were implanted on the dorsal side of mice. Inflammatory wound cells were harvested on d1 and 3 (early) or d7 (late) phase. Flow cytometry data shows that at d3 post wounding, the majority (>70%) of cells harvested from sponge were macrophages (F4/80+), while 25% of the cells were PMN (Gr-1+). RNA was extracted from the inflammatory wound cells on d1, 3 or 7 post-implantation and pro- and anti-inflammatory gene expression was studied. In d1 & 3, expression of pro-inflammatory genes TNF-α and IL-1β were significantly up-regulated ($p<0.05$, $n=4$) by MCG. Later, on d7, levels of TNF-α and IL-1β were sharply lower ($p<0.05$, $n=4$) in the MCG treated group. At the same time point, anti-inflammatory cytokine IL-4 was significantly up-regulated in MCG treated group. These observations indicate that MCG transiently mounts robust inflammatory response followed by rapid resolution. Previously we had reported that macrophage efferocytosis helps switch these cells from pro-inflammatory to anti-inflammatory phenotype leading to resolution of wound inflammation. MCG improved macrophage efferocytosis and increased VEGF production compared to saline treated group providing for a mechanism by which MCG may help resolve inflammation and support wound angiogenesis. Taken together, MCG is known to improve wound healing in pre-clinical swine models. Here we note that MCG may achieve that outcome by its effect on the wound inflammation process.

By Jonathan Moore, DPM, MS, MA

Examining The Potential Of Collagen Powders In The Diabetic Foot

While collagen powders are not new to the market, they have recently become among the more commonly used advanced wound care products, especially among podiatric physicians. As more physicians and wound care specialists are looking for more rapid and economical alternatives to enhance wound healing, collagen powders can be extremely effective.

Needless to say, what you take off a wound (debridement) is still more important than what you put on it. Proper wound debridement, offloading and moisture balance remain critical no matter what you put on a wound.[1] Certainly, maintaining a debris-free wound is still key to wound healing. While the most obvious benefits of collagen powder are the ease of use and cost, the powder form of a collagen protein has immediate bioavailability for the wound bed, thereby enhancing wound healing.

In addition to immediate bioavailability, collagen powder allows for greater diffusion over the surface of the wound bed. Enhanced wound contact and bioavailability stimulate the body's own tissue repair. A more recent understanding of the natural shape and function of collagen in wound healing has helped practitioners be more educated about their wound healing options.

Among patients with diabetes and wounds, we know that type 1 collagen is in deficit along with normal fibroblast proliferation.[2] Overall, we can say with some confidence that collagen enhances the wound contracture and cellular migration that are essential for wound healing.[3,4]

Type 1 collagen is essential for the release of growth factors by the extracellular matrix, which also serves to store and protect growth factors. However, when the extracellular matrix is disrupted, loss of tissue and bacterial overgrowth can occur.[5]

As most collagen powders come in sterile packages, it is only natural for some physicians to attempt to "sprinkle" the powder over the wound in order to achieve the proper application. While this may work in some situations, it can often be difficult to administer adequate amounts of the product on the target site without creating waste. Instead, use a tongue depressor to gather a small scoop of collagen powder on its flat edge.

As integrin interaction with collagen influences the ability of macrophages, fibroblasts and endothelial cells to migrate and attach themselves, type 1 collagen in turn becomes essential in order to recruit macrophages and monocytes. Interestingly, this chemotaxis process is concentration dependent, meaning the more collagen, the stronger the stimulus.[6]

Collagen breakdown occurs naturally as the result of metalloproteases like collagenase or through some other type of trauma or enzymatic erosion. However, when this process occurs, these collagen fragments stimulate the infiltration of macrophages and fibroblasts in the wound bed. Moreover, the body recycles leftover exposed amino acids from this fragmentation process and uses them for the production of new proteins for enhanced wound healing.

In theory, the laboratory fragmentation of collagen will result in the creation of more active sites in the wound for the binding of fibronectin and improved fibroblast viability.

Collagen fragments in the form of a collagen powder created as the result of hydrolyzation or some other patented process will in the same fashion improve fibroblast viability and cellular response to stress, and better modulate protease activity. Accordingly, these collagen fragments will serve to guide fibroblasts along the connective tissue matrix to achieve better wound healing.

Transport the powder to the wound edge and apply it by rotating the depressor directly to the wound site. The collagen will immediately begin to absorb the wound fluids as it adheres to the site.

While all collagen powders undergo some fragmentation process for the aforementioned purposes, the way in which fragmentation occurs differs among available products on the market. Most collagen powder products on the market "fragment" their collagen using a hydrolyzation process. These products include Stimulen (Southwest Technologies) and CellerateRx (Wound Care Innovations).

Non-hydrolyzed collagen products retain significantly more native triple helical protein structure, thereby allowing for better stability of the molecule and scaffolding in wound healing. The main purposes of collagen in wound healing are providing integrity and structure to the wound. When the collagen molecule is fragmented (losing its natural triple helix shape), its role shifts to more of a reparative role through its chemotactic properties (activation of monocytes, thus creating more macrophages, etc.).

The vital importance of collagen as a scaffold for wound healing lies in its ability to retain its triple helix shape, which enhances thermal stability, mechanical strength and the ability to engage in specific interactions with other biomolecules. While I have already discussed the benefits of collagen fragments for chemotaxis and fibroblast proliferation, it should be the goal of any collagen wound product to retain as much of its natural triple helix shape as possible.

Collagen powders on the market that retain some of this natural triple helix structure (Helix 3-CP, Amerx Health Care) may enable better scaffolding and cell migration for the creation of granulation tissue.

Without question, collagen-based wound dressings are ideal for chronic wounds by addressing elevated levels of matrix metalloproteinases (MMPs), which degrade both viable and non-viable collagen.

Without the proper formation of the scaffold needed for cell migration, the formation of the extracellular matrix and granulation tissue will be significantly altered. Collagen-based dressings also have the ability to absorb excess wound exudate while maintaining a moist environment for wound healing.[8]

Billing Pearls For Collagen Powders

Medicare reimburses collagen powders with the code A6010. Products like collagen powders have coverage when they meet either of the following criteria:

1. They are required for the treatment of a wound caused by or treated by a surgical procedure; or
2. They are required after debridement of a full-thickness wound.

Surgical dressing codes require the use of modifiers A1-A9 (A1 = one wound; A2 = two wounds, etc.). One may dispense up to 30 units (one unit = 1 gram) per wound every 30 days as needed. As physicians send any wound dressing being billed to insurance home with the patient, claims submitted to the durable medical equipment regional carrier (DMERC) will use the place of service code (POS=12) corresponding to the patient's residence. Do not use the place of service office code (POS=11). Additionally, patients who are under any home health status (even services not related to the wound) are not eligible for the billing of wound care products to DMERC. Medicare will deny claims for wound care-related dressings (even compression garments) if the patient is still under any home health designation. It is always wise to confirm the patient's status before billing wound dressings.

Dressing size and quantity must be based on and appropriate to the size of the wound. Dressing needs may change frequently (e.g., weekly/daily) in the early phases of wound treatment and/or with heavily draining wounds. Suppliers are also expected to have a mechanism for determining the quantity of dressings that the patient is actually using and to adjust their provision of dressings accordingly. One may provide no more than a one-month supply of dressings at one time unless there is documentation to support the necessity of greater quantities in the home setting in an individual case. An even smaller quantity may be appropriate.

One must tailor surgical dressings to the specific needs of an individual patient.

A Guide To Collagen Powders

	Non-hydrolyzed	Hydrolyzed	Hydrolyzed
Product name	Helix 3-CP	Cellerate Rx	Stimulen
Manufacturer	Amerx Health Care	Wound Care Innovations	Southwest Technologies
Description	Collagen powder	Collagen fragments	Collagen powder
Material	100%- type 1	Approximately 95% type 1	Modified collagen
Source	Bovine	Bovine	Bovine
Cost	$13	$19.25	$15

Ideal results will occur if there is adequate powder to fill the wound and when the area is moist to facilitate incorporation of the collagen into the wound.

When surgical dressings come in kits, Medicare covers only those components of the kit that meet the definition of a surgical dressing that the physician orders and those that are medically necessary.

(Disclaimer: This information does not guarantee reimbursement but provides guidance for accurate documentation and appropriate usage for collagen wound care supplies. Should you need further technical assistance or have specific coding questions, please contact your DMERC or other intermediary.)

How To Apply Collagen Powders

As most collagen powders come in sterile packages, it is only natural for some physicians to attempt to "sprinkle" the powder over the wound in order to achieve the proper application. While this may work in some situations, it can often be difficult to administer adequate amounts of the product on the target site without creating waste.

My preferred method of application entails the utilization of a sterile tongue depressor for ease of applications and reduction of waste. Use the tongue depressor to gather a small scoop of powder on its flat edge. Then transport the powder to the wound edge and apply it by rotating the depressor directly to the wound site. The collagen will immediately begin to absorb the wound fluids as it adheres to the site. Ideal results will occur if there is adequate powder to fill the wound and when the area is moist to facilitate incorporation of the collagen into the wound.

Supplementing the wound site with sterile saline or some other type of hydrogel is appropriate as long as there is not excessive moisture, and as long as one does not wash or flush the powder out of the wound.

Case Study: How The Use Of Collagen Powder Helped Heal A Diabetic Neuropathic Ulcer

A 55-year-old patient with diabetic neuropathy, deformity and significant contracture of his digits presented with a Grade 2 diabetic ulcer as a result of poor fitting shoes. After a comprehensive diabetic foot exam and X-rays (revealing no osteomyelitis), I debrided the wound, flushed it and applied Helix 3 Collagen Powder (Helix 3-CP) to the wound bed followed by a 2x2 gauze pad and Coban.

The wound was adequately moist so no supplemental moisture was needed. The patient received education regarding how to use and apply the product at home (daily application after cleaning with sterile saline) and I dispensed a one-month supply of Helix 3-CP to the patient following the billing protocol above.

Due to the patient's deformity and neuropathy, I dispensed a post-op shoe with a diabetic orthotic to the patient in order to keep the hallux from rubbing.

If the patient had not been able to apply the dressing at home or required assistance, I would have dispensed the product and then called home health to come in and provide care with the product I dispensed.

As I mentioned above, if the patient were already in home health, I would not have been able to dispense the product through the office. I would have then had to write a prescription for the product for home health to order and use.

I saw the patient weekly for four weeks. The wound was completely closed by the fourth week.

In Conclusion

Despite limited studies, wound dressings containing collagen clearly provide some benefit in the treatment of diabetic foot ulcers and one should consider them among the myriad of wound dressings available to clinicians. Though there are several collagen powders on the market, there has not been sufficient evidence to prove the superiority of a particular collagen biological source or combination over another.

In choosing the best collagen powder for the clinic, one should take into account cost, the properties of the collagen, and the ease of use and availability.

As with any wound product, proper debridement, offloading and education are critical. Lastly, providing wound care products for your patients in the office can also be a tremendous convenience for your patients as well as financial benefit for your practice. ■

Dr. Moore has a Masters Degree in Medical Education and is in private practice in Somerset, Ky. He is a frequent writer and lecturer, and serves on the board of the American Academy of Podiatric Practice Management. Dr. Moore is a former Diabetic Foot Fellow at the University of Texas Health Science Center. Dr. Moore has disclosed that he is a lecturer and consultant for Amerx Health Care Corp.

References

1. Falanga V. Classifications for wound bed preparation and stimulation of chronic wounds. *Wound Repair Regen.* 2000;8(5):347-352.
2. Black E, Vibe-Petersen J, Jorgensen LN, et al. Decrease of collagen deposition in wound repair in type 1 diabetes independent of glycemic control. *Arch Surg.* 2003;138(1):34-40.
3. Smith KJ, Skelton HG Barrett TL, et al. Histologic and immunohistochemical features in biopsy sites in which bovine collagen matrix was used for hemostasis. *J Am Acad Derm.* 1996;34(3):434-438.
4. Kolenik SA, McGovern TW, Leffell DJ. Use of a lyophilized bovine collagen matrix in postoperative wound healing. *Dermatol Surg.* 1999;25(4):303-307.
5. Schultz G, Wysocki A. Interaction between extracellular matrix and growth factors in wound healing. *Wound Repair Regen.* 2009; 17(2):153-62.
6. Postlethwaite AE, Kang AH. Collagen and collagen peptide-induced chemotaxis of human blood monocytes. *J Exp Med.* 1976; 143(6):1299-1307.
7. Shoulders MD, Raines RT. Collagen structure and stability. *Ann Rev Biochem.* 2009; 78:929–958.
8. Holmes C, Wrobel JS, Maceachern MP, Boles BR. Collagen-based wound dressings for the treatment of diabetes-related foot ulcers: a systematic review. *Diabetes Metab Syndr Obes.* 2013; 6:17–29.

The Effects Of Powdered Collagen On Chronic Wounds

Sharon Leslie RN, BSN, WCS • Tawnya Bothwell RN, BSN, CWCN
Yakima Valley Memorial Hospital

Purpose

Two case studies demonstrating the effectiveness of powdered collagen on chronic wounds.

Objectives

At the conclusion of this presentation the participant will be able to:

1. Identify 2 types of wounds that can be treated with powdered collagen.
2. List different cover dressings that are compatible with powdered collagen.
3. Describe the frequency of dressing changes in effective powdered collagen use.

Abstract

Powdered collagen can be used in wound care to stimulate fibroblast production and growth factors that create angiogenesis. There are many types of wounds that can benefit from powdered collagen application; it can be used in a cavity and it can be used anywhere on the body.

Case Study #1: A very active 55 year old patient with chronic venous insufficiency and a history of DVT Factor V Leiden. Patient has a history of previous chronic wounds. This wound first presented as dry, fibrin-filled with significant hemosiderin staining in the LLE. The wound was cleansed with saline; powdered collagen was applied under a glycerin hydrogel sheet; and then an unna boot compression wrap was applied twice weekly.

Case Study #2: This 55 year old patient had initial trauma to the right pretibial area and has had an open wound since 1990. After the trauma, it was used as an injection site for black tar heroin. Comorbidities include sleep apnea, COPD, asthma, hypertension, chronic pain, chronic nicotine use, venous insufficiency, and polysubstance abuse. Patient's wound was cleansed with a hypoclorous acid solution for 10 minutes prior to each dressing change and/or debridement; powdered collagen covered with foam and later a cadexomer iodine pad was applied to the wound bed under an unna boot compression wrap twice weekly. This product prepared a sufficient granular base for a split thickness skin graft.

Conclusion

During our trial, we observed rapid improvement of granulation tissue in two chronic wounds. We used powdered collagen to promote granulation tissue and encourage epithelial growth from the wound edges. We would recommend collagen use for stalled wounds, chronic wounds and wounds that are slow to heal anywhere on the body.

Case #1:

This 55 year old patient has chronic venous insufficiency with a history of DVT Factor V Leiden. He is an extremely active individual and is also self-pay. His significant other was taught to wrap the lower extremity with an unna boot and when the wound stalled 1/25/11, she was taught to used Coban 2 compression wrap. The wrap was changed twice weekly. We used a powdered collagen dressing under the compression wraps. His wound progressed nicely to closure 3/8/11.

Photo #1 (10-12-10):
Bi-weekly *collagen powder with *compression wrap

Photo #2 (11-23-10):
Bi-weekly *collagen powder, *glycerine gel sheet with *compression wrap

Photo #3 (1-25-11):
Bi-weekly *collagen powder, secured with *stretch wrap

Photo #4 (3-8-11):
Closed

Case #2:

This 55 year old patient had initial trauma to the right pretibial area when it was hit with a lead pipe in 1990. After the trauma, it was used as an injection site for black tar heroin. The wound has been open since 1990. Comorbidities include sleep apnea with CPAP treatment, COPD with chronic bronchitis, asthma, hypertension, chronic pain, chronic nicotine use and a history of polyssubstance abuse. He has a 40 year history of smoking 2.5 ppd. Patient was wrapped two times a week with unna boots. The patient was thrilled with his result because he healed more in 2 months with this product than he had with any product used in 10 years. This product prepared a sufficient granular base for his split thickness skin graft.

Photo #1 (7-6-10):
Early photo, treated with bi-weekly *silver dressing, *compression wrap

Photo #2 (11-2-10):
Bi-weekly *collagen powder, foam, *compression wrap

Photo #3 (12-14-10):
Bi-weekly *collagen powder, *antimicrobial, *compression wrap

Photo #4 (1-11-11):
Stopped *collagen powder, *antimicrobial, *compression wrap(planned skin graft)

Products used in Case Studies:

- *Stimulen™ Collagen Powder*
- *Silvercel™ Silver Dressing*
- *Coban 2™ Stretch Wrap*
- *Elasto-Gel™ glycerin hydrogel sheet*
- *Iodoflex* antimicrobial*
- *Profore* Compression Wrap*

References

Brett D. A review of collagen and collagen-based wound dressings. [Electonric version]. Wounds. 2008; 20 (12).

Niezgoda J, Sordi PJ, Hermans M. Evaluation of vashe wound therapy in the clinical management of patients with chronic wounds. Adv Skin Wound Care 2010;23:352-356.

Stacey M, Falange V, Marston W, Moffott C, Phillips T, Sibbald G, Vanscheidt W, Lindham C. The use of compression therapy in the treatment of venous leg ulcers: a recommended management pathway. EWMA Journal 2002;2(1).

Phillips PL, Wolcott RD, Fletcher J, Schultz GS. Biofilms made easy. [Electronic version]. Wounds International 2010;1(3).

Clinical Symposium on Advances in SKIN & WOUND CARE

The Conference for Prevention and Healing

September 9-12, 2011

Gaylord National Hotel
& Convention Center

National Harbor, MD

Presentation supported by

phone: (800) 247-9951 • email: info@elastogel.com • website: www.elastogel.com

southwest technologies inc.

"Treating the world well"®

1746 Levee Road, North Kansas City, MO 64116
ph: (800) 247-9951 ph: (816) 221-2442 fax: (816) 221-3995
email: info@elastogel.com • web site: www.elastogel.com

PEDIATRIC TRAUMA MANAGEMENT

Jeremy Bledsoe, NREMT • Diana Gallagher MS, RN, CWOCN, CFCN

ABSTRACT

CS-067

On August 27, a 12 year old sustained significant trauma to ring and pinky fingers when the heavy lid of a commercial dumpster became dislodged. The fingers were pinned between the base and lid. The natural reaction was to pull away causing significant degloving. The initial trauma resulted in bone exposure on both fingers and a micro fracture of the distal knuckle of the pinky finger.

The patient was initially seen by an Emergency Department physican, a plastic surgeon, and an orthopedic hand surgeon. The wounds were sutured and over the course of the next month, 35 stitches were removed. The fingers were wrapped with petroleum gauze and topped with dry gauze. Followup care the following week created additional trauma when an attempt was made to remove the dressings. The petroleum gauze had dried, tightly incorporating into the wounds. Attempts to remove the petroleum gauze were not successful even after soaking for over 30 minutes in hydrogen peroxide. Parts of the petroleum gauze were cut away; however not all of the dressing could be removed.

He was seen the following week by the orthopedic surgeon. Ten sutures were removed along with additional dried petroleum gauze dressing. The process was very painful and stopped when the patient could not tolerate any more. Because patient's father was familiar with Southwest Technologies Inc., he suggested a change in the treatment plan.

On September 4, the patient was started on a combination of Stimulen® gel and Stimulen® lotion over the suture lines and the surrounding eschar that had resulted from the dry dressings. The fingers were then covered with a 4"x 4" piece of Elasto-Gel™ creatively cut into the shape of a Greek cross. Each leg of the cross was fashioned over the sides of the fingers. The four sides were gently taped into place and secured with a Finger Bob® elastic tubular bandage for digits.

Twice weekly, the wounds on both fingers were cleaned and redressed. Range of motion exercises were incorporated into the plan of care. Additional sutures were removed with each visit. On October 13, what was thought to be the final suture was removed from under the nail.

In just over 5 weeks, the wounds healed without complications. There is minimal scarring, normal sensation, and full range of motion has been restored. The atraumatic dressing changes allowed the patient to participate in care without sedation and without the emotional trauma that can occur with apprehension and fear.

08-27-2014

08-27-2014

08-27-2014

09-05-2014

09-12-2014

09-30-2014

10-06-2014

10-15-2014

10-15-2014

Managing Pain and Minimizing Fear in a Pediatric Patient

Children and adolescents deserve special consideration when it comes to wound management. It is important to remember that these patients are not just "little adults". Reasoning and logic will not be effective tools when trying to overcome fear and apprehension.

In this case study, the patient is 12 years old. The initial trauma was exquisitely painful. The original repair was managed with light sedation in the Emergency Department. The first followup visit to the orthopedic surgeon's office left a lasting, negative imprint because of the pain and trauma that was created with the attempts to remove the dry, adherent dressing. Sadly, the second visit was equally memorable because of the difficulty removing sutures from the swollen, bruised digits. When the treatment plan was changed to incorporate moist wound healing, our young patient's perception of the situation changed. The patient's perception of pain was respected; the patient was allowed some control; the patient was given a voice; and, pain was minimized.

A growing number of studies address pediatric pain. Even transient pain can have a lasting affect on a young patient. In a study published in Pediatrics, it was shown that timely pain management can have a lasting effect on a child's and family's reaction to current and future medical care. Another study recognized the growing recognition that even minor painful procedures, such as needle sticks, can affect a child's long term emotional well-being. Based on the growing evidence base, we all have a responsibility to assess and minimize pain whenever possible.

Both the Stimulen® and Elasto-Gel™ products used on this patient contributed to moist wound healing and reduced pain. Stimulen® helped accelerate wound healing and manage the inflammatory wound phase. Because the original trauma was a crushing injury, tissue and blood vessels were compromised. Stimulen® has been shown to heal even avascular wounds with its ability to grow new blood vessels. Elasto-Gel™ is a "smart" dressing. The glycerin-based solid hydrogel has a number of properties that are responsible for decreased pain. Glycerin is a humectant which will maintain moist healing as well as absorb mild to moderate exudate. The dressing itself is soothing and cooling upon application. Both adults and children enjoy this sensation as opposed to dressings that may be painful. Elasto-Gel™ allows for atraumatic dressing changes. It has also been proven to maintain a consistent temperature which aids in both decreased time to wound healing and decreased pain. The bacteriostatic/fungistatic properties of this dressing helps reduce bacterial counts, bioburden, and infection. Regardless of a patient's age, pain management should always be a priority. Southwest Technologies Inc. synergistic products hold the answer to pain management.

[1] *PEDIATRICS Vol. 130 No. 5 November 1, 2012 pp. e1391 -e1405 (doi: 10.1542/peds.2012-2536)*

[2] *Walco GA. Needle pain in children: contextual factors. Pediatrics. 2008;122(suppl 3):S125–S129*

[3] *Wound Repair & Regeneration, Nov 2014*

southwest technologies inc.
1746 Levee Road, North Kansas City, MO. 64116 • ph:(800) 247-9951 ph:(816) 221-2442 fax:(816) 221-3995 • email: info@elastogel.com • www.elastogel.com

Clinical Case Studies Demonstrating Impressive Healing of a Post-Operative Wound, Pressure Ulcer, Traumatic Wound and Venous Stasis Ulcer Utilizing Collagen Products

Clinicians: Ruth Anderson, RN, CWS and Char Wilkening, RN, CWS
Boone County Hospital, Boone, Iowa

ABSTRACT

Five Cases of diverse wounds are presented:

Case #1: Morbidly obese diabetic with non healing traumatic wound complicated by venous insufficiency. Wound cleansed daily, covered with collagen glycerine gel sheet* and covered with a non-adherent dressing. Healed in seventy one days.

Case #2: Non healing partial thickness 95% slough covered wound medial lower leg. Cleansed weekly and wound filled with collagen powder**. Four layer compression wraps applied. Healed in sixty-four days.

Case #3: Diabetic with intravenous extravasation with full thickness wound of finger with tendon exposed. Daily cleansing, wound covered with collagen glycerine sheet*. Healed in seventy days.

Case #4: Diabetic quadriplegic with Stage IV pressure ulcer of lateral foot with tendon exposed. Daily cleansing, wound covered with collagen glycerine sheet*. Healed in seventy-eight days.

Case #5: Post-operative triple by-pass with non healing donor site. Wound cleansed daily, filled with collagen glycerine gel***, covered with foam. Healed in twenty days.

Conclusion - The collagen products were effective in stimulating rapid granulation of these non healing wounds.

Objectives - After viewing this poster presentation the participant will be able to formulate a treatment plan utilizing an easy to use collagen or collagen glycerine product.

Rationale - The collagen product was selected after wounds failed to heal with previous treatment plans.

Presented at the 20th Anniversary Clinical Symposium on Skin and Wound Care
October 23-26, 2005 • Las Vegas, NV

Case #1:

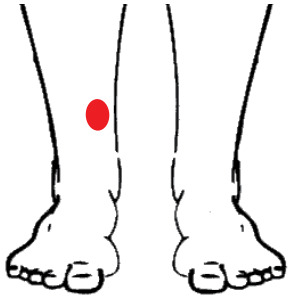

A thirty-eight year old morbidly obese diabetic female with a one month non healing traumatic wound of the right lower leg complicated by venous insufficiency.

Photo #1: - (12/30/04) The patient presented to clinic with a one month duration partial thickness wound due to trauma. The diabetic patient's weight was 460 pounds. Previous history revealed a non healing lower leg wound requiring three months to heal. Initial assessment of the wound revealed a 75% slough filled wound measuring L1.0cm x W1.7cm with a depth of 0.1cm.

Protocol - The wound was cleansed daily with a shower, then collagen glycerine sheet* was used to cover the wound bed and covered with a non-adherent dressing. The patient was instructed to wear knee high compression stockings.

Photo #2: - (01/13/05) Two weeks later the slough had decreased to 10%. The wound measured L0.9cm x Wl.2cm and no depth. At five weeks into treatment the wound measured L0.5cm x W0.8cm.

Photo #3: - (02/24/05) At six weeks into the collagen glycerine gel sheet* treatment the wound measured L0.4cm x W0.5cm.

Photo #4: - (03/10/05) Seventy-one days after initiating treatment the wound was healed with no signs of infection.

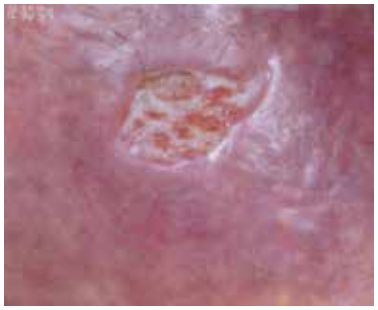

Photo 1: 12/30/04

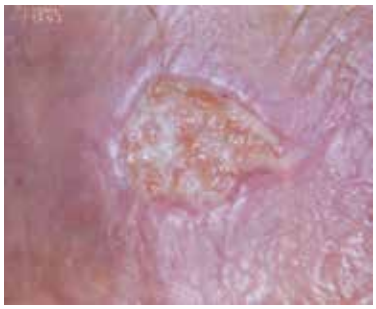

Photo 2: 01/13/05

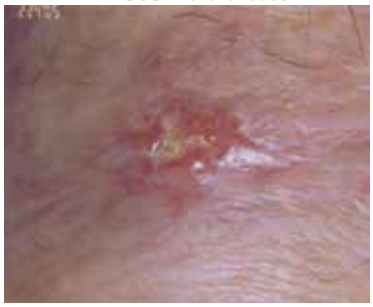

Photo 3: 02/24/05

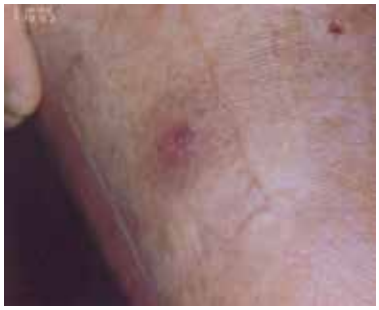

Photo 4: 03/10/05

Case #2:

A seventy-one year old male post-op coronary by-pass with a 95% slough filled non healing wound of the graft site.

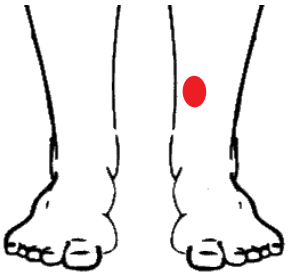

Photo #1: - (10/28/04) The patient presented to the clinic with a non healing 95% slough covered partial thickness post-op wound of the left lower leg with a ABI (ankle brachial index) of 1.13cm. The wound measured L2.4cm x W0.7cm with a depth of 0.6cm. Heavy serosanguinous drainage was present.

Protocol - The wound was cleansed weekly and the wound bed was covered with silver-sulfadiazine cream and collagen powder** sprinkled over to fill the wound bed and the leg was then wrapped with a four part compression wrap.

Photo #2: - (11/04/04) One week later the slough was decreased to 50% and measured L2.2cm x W0.4cm with a 1.0cm depth.

Photo #3: - (11/18/04) At three weeks into treatment the wound measured L2.0cm x W0.3cm with a depth of 0.3cm with minimal slough and 95% vascularized.

Photo #4: - (12/30/04) After sixty-four days of treatment the wound was healed.

Photo 1: 10/28/04

Photo 2: 11/04/04

Photo 3: 11/18/04

Photo 4: 12/30/04

Case #3:

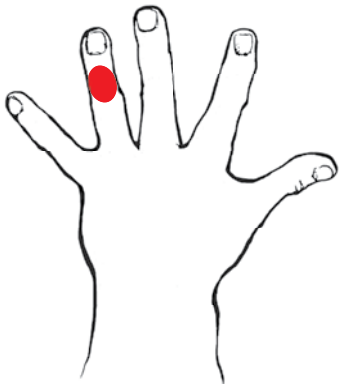

A forty-eight year old diabetic with a 100% eschar covered fourth digit due to an intra-venous infiltration with resulting extravasation.

Photo # 1: - (08/05/04)
The patient presented to clinic with a 100% eschar covered fourth digit. The wound measured L6.0cm x W4.0cm. No viable tissue was visible.

Protocol - The wound was cleansed daily and a glycerine hydrogel sheet**** was applied. This treatment continued with weekly debridement and clinic visit for four weeks.

Photo 1: 08/05/04

Photo #2: - (09/08/04)
After four weeks of treatment the wound was slough free but with tendon exposed. The wound measured L4.5cm X Wl.2cm. The protocol was changed to daily cleansing and covered with a collagen glycerine sheet* and secured with gauze and Kling®.

Photo 2: 09/08/04

Photo #3: - (10/28/04)
The wound showed no signs of infection and continued to progress well. Six weeks after initiating the collagen glycerine sheet* the wound measured L1.5cm x W0.5cm and the tendon was completely covered and the wound bed was 100% vascularized.

Photo 3: 10/28/04

Photo #4: - (11/11/04)
After seventy days of treatment the wound was completely healed with no infection and minimal scarring.

Photo 4: 11/11/04

Case #4:

A forty-eight year old diabetic quadriplegic with a Stage IV pres-sure ulcer of the lateral foot with tendon exposed.

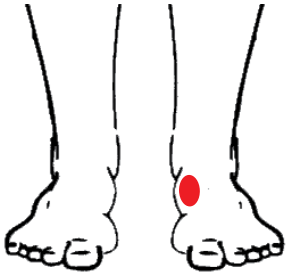

Photo #1: - (09/28/04)
Initial visit on 9/28/04. The patient presented with a L1.2cm x W2.4cm eschar covered pressure ulcer of the lateral foot.

Protocol - The wound was cleansed daily and covered with a glycerine gel sheet**** to soften the eschar which was accom-plished within two weeks of treatment and was continued for one month to further debride the wound.

Photo 1: 09/28/04

Photo #2: - (11/11/04)
Following seven weeks of utilizing the glycerine gel sheet****, exposed tendon was vascular-ized. The wound

Photo 2: 11/11/04

measured L1.2cm x W3.0cm.

Protocol - The wound was cleansed daily and covered with a collagen glycerine sheet* and secured with Kling®.

Photo 3: 12/30/04

Photo #3: - (12/30/04) After six weeks of treatment the wound measured L0.5cm x W0.5cm and the tendon was covered and granulation tissue was present. The collagen glycerine gel sheet* was continued with healing occurring in seventy-eight days with no infection or surgical closure required.

Case #5:

A forty-seven year old post-op triple by-pass patient with a non healing donor site.

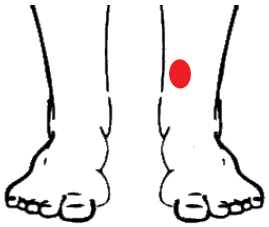

Photo #1: - (09/23/04) The patient presented with a non healing post-op wound of the lower leg following triple by-pass surgery. The previous treatment had been packing the wound with gauze dressing. On admission the wound measured L0.7cm x Wl.0cm and revealed 50% slough.

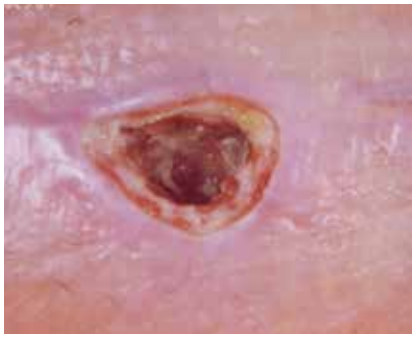

Photo 1: 09/23/04

Protocol - The original treatment was continued for six weeks as ordered by the physician. The wound continued to be non healing.

Photo #2: - (11/04/04) At this clinic visit the wound measured L0.5cm x W0.6cm with a depth of 0.6cm with minimal improvement and an order for collagen glycerine gel*** was obtained.

Photo 2: 11/04/04

Protocol - The wound was cleansed daily with shower, applied collagen glycerine gel*** to the wound bed and covered with foam.

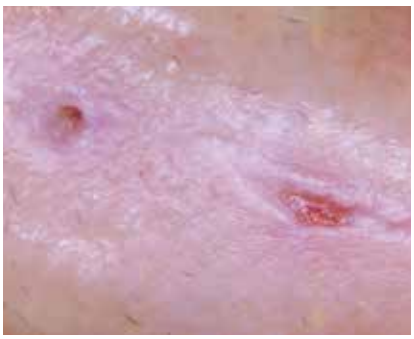

Photo 3: 11/11/04

Photo #3: - (11/11/04) One week after initiating treatment with the collagen glycerine gel*** the wound measured L0.lcm x W0.lcm with a depth of 0.lcm.

Protocol - Continue collagen glycerine gel*** and cover with foam.

Photo 4: 11/23/04

Photo #4: (11/23/04) - Twenty days after initiating the collagen glycerine gel*** the wound was completely healed.

References

Baranoski, Sharon (MSN, RN, CWOCN, APN, FAAN), Ayello, Elizabeth A. (PhD, RN, APRN, BC, CWOCN, FAAN), Wound Care Essentials, Lippincott Williams & Wilkins, 2003

Bryant, Ruth (RN, MC, CWOCN), Acute Chronic Wounds, Nursing Management, USA: Mosby Inc., 2000

Habit, Thomas P., Cambell Jr. James, L., Quitadamo, Mark J., Zug, Kathryn A., Skin Disease (Diagnosis and Treatment), USA: Mosby Inc., 2001

Thomas Hess, Cathy (RN, BSN, CWOCN) "Care Tips for Chronic Wounds: Pressure Ulcers", Skin & Wound Care, The Journal For Prevention and Healing, vol. 17, page 477-478, November 2004

Products used:

- * Stimulen™ Gel Sheet
- ** Stimulen™ Collagen Powder
- *** Stimulen™ Collagen Amorphous Gel
- **** Elasto-Gel™ Glycerine Gel Sheet

Clinicians: Ruth Anderson, RN, CWS and Char Wilkening, RN, CWS

Boone County Hospital, Boone, Iowa

Clinical Case Studies Utilizing Hydrolyzed Collagen Powder* To Effectively Heal A Variety Of Wounds

Ruth E. Anderson RN, CWS; Charlene Wilkening RN, CWS; Cathy Wetzeler RN, CWOCN • Boone County Hospital, Boone, IA

Abstract

Objectives: #1. After viewing this poster presentation the participant will be able to formulate an effective treatment plan utilizing a hydrolyzed collagen powder* to enhance rapid healing.
#2. The participant will be able to describe two benefits of utilizing this relatively new product.

Rationale: This absorptive, 100% hydrolyzed collagen product* was selected for its ability to stimulate fibroblastic activity as well as its ease of application.

Case #1: A fifty-six year old diabetic, hypertensive, obese patient with large partial thickness undermined wounds of the buttocks. Wounds cleansed daily, hydrolyzed collagen powder* sprinkled on gauze dressing and applied to wound. Healed in thirty days.

Case # 2: A seventy-two year old diabetic, hypertensive patient with a five month duration non-healing post surgical wound of the left foot. Wound cleansed daily, hydrolyzed collagen powder* to wound bed, covered with foam. Healed in ten days.

Case #3: A seventy-five year old obese patient with peripheral vascular disease and previous chronic slow healing leg ulcers. Partial thickness wounds of bilateral lower legs. Weekly cleansing of all wounds, filled with hydrolyzed collagen powder*, covered with foam dressing and compression wraps. Healed in eighty-five days.

Conclusion: The hydrolyzed collagen powder* stimulated fibroblastic activity within one week and promoted healing in those vascular compromised wounds. Hydrolyzed collagen powder* requires non-physician application, was easy for the patient to apply, absorbed excess fluids effectively with comfort, and had great healing outcomes.

SAWC & WHS 07

April 28th- May 1st, 2007 • Tampa, Florida

Clinical Case Studies Utilizing Hydrol
Heal A Variet

Case #1:

A fifty-six year old obese hypertensive diabetic with a large partial thickness tunneling and undermining wounds of the buttocks.

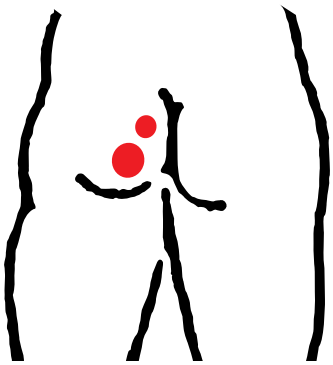

Photo #1 (3-2-06): The patient presented to wound clinic with two connecting wounds on the buttock. The wounds occurred following the progression of a "sore rectal area" to open wounds draining copious amounts of foul smelling drainage. The patient sought medical attention and was placed on an oral antibiotic and referred to the outpatient wound clinic. Initial assessment of the wounds revealed partial thickness, connecting pale red wound beds. The proximal wound measured L 1.2 cm x W .6 cm with a depth of .9 cm. The distal wound measured L 3.4 cm x W 3.0 cm with tunneling of 5.5 cm.

Protocol: The patient was instructed to daily cleanse the areas during showering. Application of a silver hydrogel and covered with a gauze dressing.

Photo #1 (3-2-06)

Photo #2 (3-16-06)

Photo #2 (3-16-06): Distal wound measured L 2.3 cm x W 2.7 cm with a depth of 0.4 cm with undermining at 3 o'clock of 3.0 cm and 9 o'clock of 0.4 cm. The proximal wound measured L 0.2 cm x W 0.5 cm with no depth. The wound now presented as beefy red with moderate serosanguineous drainage.

Protocol: The treatment plan was changed to hydrolyzed collagen powder*, to be applied by the patient daily. Application was simplified for independent application to a precarious area by applying the powder on a gauze pad and secured.

Photo #3 (3-30-06)

Photo #4 (4-13-06)

Photo #3 (3-30-06): Distal wound measured L 0.9 cm x W 1.8 cm with a depth of 0.4 cm. 3 o'clock undermining was 0.4 cm and 9 o'clock undermining was healed. The proximal wound was healed, 100% granular and contracting. The distal wound continued to be beefy red with scant serosanguineous drainage.

Photo #4 (4-13-06): Distal wound healed with scar tissue formation after thirty days of initial treatment. There were no signs or symptoms of infection.

Case #2:

A seventy-one year diabetic, hypertensive patient with a five month duration, non-healing post surgical wound of the left foot.

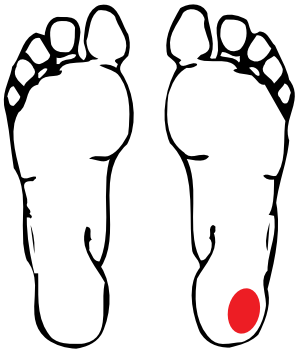

Photo #1 (12-22-05): The patient presents with a left heel pressure wound. L 1.3 cm x W 2.0 cm and 100% slough filled. The wound had deep pink edges with slight peripheral edema.

Protocol: the patient was treated by cleansing the wound and applying a hydrocolloid. The dressing was left in place for one week.

Photo #1 (12-22-05)

YZED COLLAGEN POWDER* TO EFFECTIVELY
TY OF WOUNDS

Photo #2 (1-5-06): Heel wound measures L 1.4 cm x W 0.6 cm with depth of 0.3 cm. Wound presented with continuous slough and increased serosanguineous drainage. Edges of the wound were macerated.
Protocol: Treatment was changed to apply an enzymatic debrider to the wound bed, skin barrier peri-wound and covered with a foam dressing daily.


Photo #2 (1-5-06)

Photo #3 (1-26-06): Heel wound now measures L 0.9 cm x W 0.3 cm with a depth of 0.2 cm with moderate serosanguineous drainage. The wound bed presented with decreased slough and decreased maceration peri-wound. No visible signs of fibroblastic growth.
Protocol: Protocol changed. Enzymatic debrider was discontinued due to decreased slough. Treatment initiated was hydrolyzed collagen powder* to be applied daily by the patient to aide in absorption and increase granulation. Covered with foam.


Photo #3 (1-26-06)


Photo #4 (2-2-06)

Photo #4 (2-2-06): Wound now measured L 0.8 cm x W 0.2 cm with depth of 0.2 cm Wound presents with increased granulation and collagen formation. Due to ease of application, compliance by patient was 100%. Patient verbalized comfort.


Photo #5 (2-9-06)

Photo #5 (2-9-06): Heel wound healed with 100% collagen formation, scar tissue after 10 days of using the hydrolyzed collagen powder.*

Case #3:

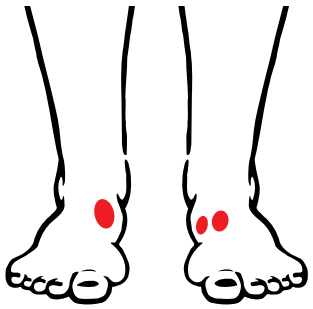

A seventy-five year old obese patient with peripheral vascular disease and previous chronic slow healing leg ulcers, partial thickness wounds of bilateral lower legs. Weekly cleansing of all wounds, filled with hydrolyzed collagen powder*, covered with foam dressing and compression wraps.

Photo #1 (12-1-05): This patient presents with partial thickness skin loss wounds to bilateral lower legs due to atherosclerotic peripheral vascular disease and a long history of non-healing wounds. Left lower leg presents with two wounds. The proximal measures L 1.1 cm x W 0.6 cm and the distal measures L 0.4 cm x W 1.2 cm, 100% granular with large amount serosanguineous drainage. The right lower medial leg presented with a wound measuring L 1.0 cm x W 1.1 cm with large serosanguineous drainage, 50% granulation and 50% slough.

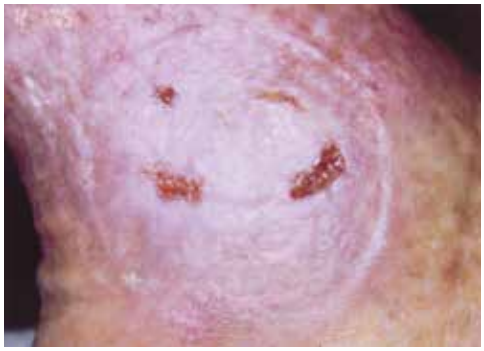
Photo #1 Left leg (12-1-05)


Photo #1 Right leg (12-1-05)

Protocol: The patient was treated by cleansing wounds then applying hydrolyzed collagen powder, foam and a four layer compression wrap. The hydrolyzed collagen powder* was applied to the wounds due to the patient's history of slow healing and diabetes.

Photo #2 (12-29-05):
Left lower leg: distal wound now measured L 0.6cm x W 1.2 cm and proximal wound measured L 1.0 cm x W 0.5 cm. The drainage was moderate, serosanguineous with 100% granulation tissue. The right leg now has one small satellite to the original wound. The original – now identified as the proximal wound measures L 1.9cm x W 1.4 cm and the right distal wound measures L 0.5 cm x W 0.3 cm with moderate serosanguineous drainage with no signs or symptoms of infection.

Photo #3 (1-12-06):
Left lower leg distal wound now measures L 0.2 cm x W 0.3 cm. drainage was now light, serosanguineous. The right lower leg wounds proximal measured L 1.9 cm x W 1.4 cm and the original distal was healed. A new satellite developed on the medial aspect of the right lower leg measuring L 0.9 cm x W 0.5 cm. The right proximal wound was measured the same but photographs reveal increased scar tissue.

Photo #4 (2-23-06):
All wounds were healed with the treatment of hydrolyzed collagen powder*, foam and a four layer compression wrap in eighty-five days, together the patient has had a history of greater than one hundred twenty days of healing per episode without hydrolyzed collagen powder*. Sent home with compression stocking therapy. Compliance remains an issue for this patient.

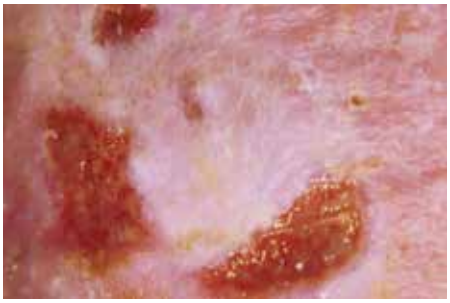
Photo #2 Left leg (12-29-05)

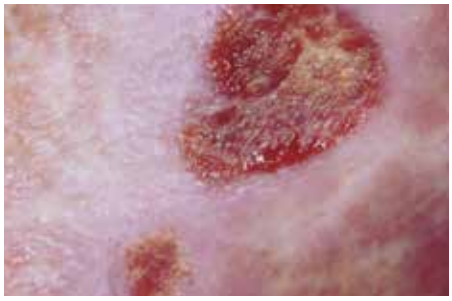
Photo #2 Right (12-29-05)


Photo #3 Left (1-12-06)


Photo #3 Right (1-12-06)


Photo #4 Left (2-23-06)

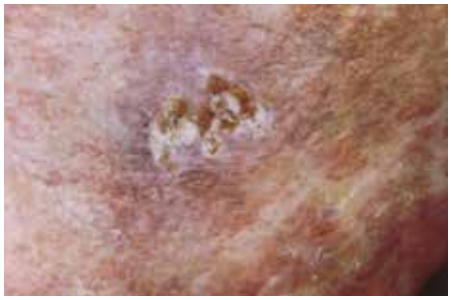
Photo #4 Right (2-23-06)

References

Baranoski, Sharon (MSN, RN, CWOCN, APN, FAAN), Ayello, Elizabeth A. (PhD, RN, APRN, BC, CWOCN, FAAN), Wound Care Essentials (Practice Principles), Lippincott Williams & Wilkins, 2004

Habit, Thomas P., Campbell Jr., James L., Quitadamo, Mark J., Zug, Kathryn A., Skin Disease (Diagnosis and Treatment), USA: Mosby Inc., 2001

Thomas Hess, Cathy (RN,BSN, CWOCN), Wound Care (Fifty Edition), Lippincott Williams & Wilkins, 2005

Product used:

* Stimulen™ Collagen Powder